

# Further correspondence concerning *Sahelanthropus tchadensis*

**S**ir — Readers following the debate about *Sahelanthropus tchadensis* in this journal need to know that the principal argument in the response by M. Brunet *et al.* to an article of ours is based on a series of CT scans and digital photos which reveal contradictions between the figure and its legend.<sup>1</sup> In our reply to this response,<sup>2</sup> we did not mention these contradictions, because we considered that it would be unlikely that they would be published as submitted. However, it is clear that:

1) There is an error in the scales, because hominid teeth a few millimetres long, as suggested by the scale, are unknown. The error is 1 to 10.

2) There is an error in the orientation of the CT scans A, for which the legend reads 'sagittal sections with mesial side at right'.

The root of M<sub>3</sub>, which descends towards the right in the scans, indicates that this is not the mesial surface but the distal one. In lower third molars, the mesial root is vertical and the distal one is inclined towards the rear of the mandible, where there is no other tooth to hinder its development. This point is clearly illustrated by photograph G in the same figure. In addition, in the two central images in line A, the planar interstitial facet, which is on the mesial surface of the third molar, occurs on the left in the image, whereas the rounded surface characteristic of the distal part of the tooth is to the right.

Examination of the sagittal section 'shot

at 3.33 mm from the buccal edge of the tooth' (the CT scan at the right-hand end) and photographs E and G, and in particular the fractures and wear pattern that the tooth possesses, show that the sagittal sections were taken respectively from the lingual margin of the tooth.

3) There is an error in orientation of the CT scans in line B, which the legend indicates are 'transversal sections with lingual side at right' — from right to left, CT scans are respectively shot at 2.67 mm, 3.69 mm, 4.11 mm, and 9.36 mm from the mesial edge of the tooth'.

If the lingual surface is to the right as indicated in the legend, then the photograph is of a left tooth. If this is so, then the text becomes incomprehensible in relation to the CT scans. Apart from that, in hominids, mastication can give rise to aberrant wear patterns. The perceived inclination of the occlusal surface can also depend on the preparation of the remnants of the roots still present just beneath the cervix of the crown and those solidly anchored in the mandible, prior to gluing the pieces together.

White<sup>3</sup> has clearly shown the problems that can be encountered during the process of sticking fragments of fossils together. In general, it is difficult to find perfect contacts between a crown and its roots if these have been separated for millions of years, encrusted separately in a hard matrix and then recently subjected to intense aeolian abrasion and strong temperature changes, which often break the teeth into fragments or polish the exposed surfaces, as has happened in the case of the mandible, or have been cleaned in the laboratory, as happened to the isolated third molar.

Comparison with photograph E reveals that, from right to left, the sections were taken respectively from the distal margin of the tooth.

4) There is an error in orientation of the

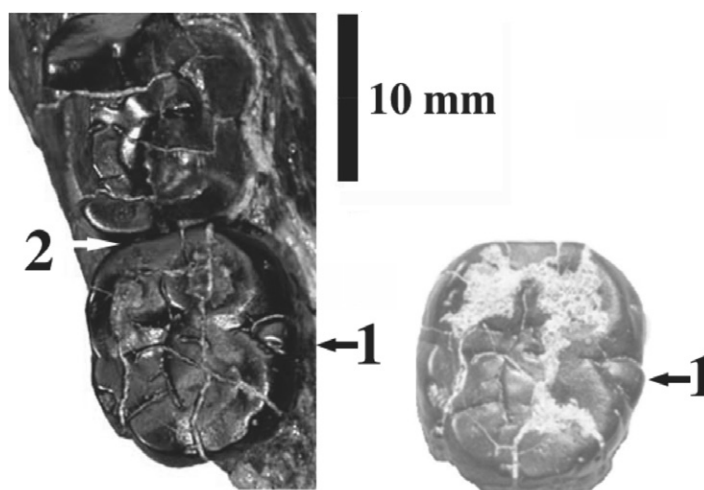
CT scans C, the legend of which states: 'Sections parallel to the occlusal surface, at the cervix level and below, with mesial side at top — from right to left, CT scans are respectively shot at 6.93 mm, 7.14 mm, 7.44 mm, and 7.80 mm from the occlusal edge of the tooth. Mesially, the mesio-buccal and mesio-lingual roots remaining in the corpus (see F) appear in light red and show exact matching with the  $M_2$  crown (in blue).'

According to the legend, the image on the right was taken closer to the occlusal surface of the tooth and the one on the left of the series closer to the mandibular body. However, the roots and the mandibular body appear in the right-hand image, which is supposed to have been taken closest to the occlusal surface, and practically disappear in the left-hand image, which is labelled as having been taken closest to the mandibular body.

It is a pity that none of the published scans or photographs shows the lateral surface of the  $M_3$  and the small cusplet that we called the metaconulid (1 in the accompanying figure), a peculiar element of this tooth. Incidentally, note that in occlusal view this accessory cusplet appears to have a mark on it (a transverse white streak in the left image) that did not exist at the time of its discovery (right-hand image). The supposed presence of a contact facet between the  $M_2$  and the  $M_3$  cannot be used to support any argument that the two teeth belong to a single individual, for the simple reason that more than two-thirds of the distal surface of  $M_2$ , that would normally possess the facet, is missing, having broken off during weathering. The remaining third of the distal surface has been subjected to aeolian abrasion (figure, left image). There thus does not exist any physical evidence of the contact between the two teeth (2 in the photograph). It is therefore not possible to affirm, as is claimed in the MPFT response, that 'the join ... is further confirmed by the matching interproximal facet preserved on the mesial surface of the tooth in question and the second molar retained by the mandible'.<sup>1</sup>

The preservation of the two fossils is very different,  $M_1$  and  $M_2$  in the mandible having suffered extensive damage by atmospheric agencies and the  $M_3$  being practically intact. Furthermore, if the  $M_3$  belongs to the mandible, then the degree of wear ought to diminish from the  $M_1$  to the  $M_3$ . However, in this case, the  $M_3$  appears to be the most worn of the teeth, showing more extensive areas of dentine than the  $M_2$ .

In the circumstances, it is astonishing that none of the 28 co-signatories grouped under the MPFT observed the numerous



The two molars,  $M_2$  and  $M_3$ , after preparation (left) and  $M_3$  at the time of its discovery. Key: 1, the small cusplet we call the metaconulid; 2, there does not appear to be any physical evidence of contact between the two teeth.

problems with their response. Equally, we fail to understand how 28 other authors, including many eminent palaeoanthropologists, after having 'carefully examined photographs and digital crown images of a fossilized third molar from the upper Miocene of Chad', could co-sign an international letter of support for the MPFT that is bereft of scientific content.<sup>4</sup>

Apart from the fact that the history of science provides no precedent for such a letter, one of the co-signatories recently proposed a list of recommendations of professional ethics.<sup>5</sup> As concerns this particular case, we mention only the following instructions from among a rich sample in what is essentially a methodological article: 'Do not publish without first examining the original', 'Do not judge the quality of a paper by its authors', 'Read every scientific paper critically', 'Do not reject papers or grant applications for personal or political reasons', as well as the comment that '...micro- and macro-computerized tomography, scanning

electron microscopy, laser scanning, ... 3D digitization, and parsimony analysis are only tools. They have no magical qualities.'

We fully endorse this excellent advice and recommend that it be taken seriously so as to reduce the possibility of scholarly misunderstanding in our field.

1. Brunet M. *et al.* (2004). *Sahelanthropus tchadensis*: the facts. *S. Afr. J. Sci.* **100**, 443–445.
2. Beauvilain A. and Le Guellec Y. (2004). *S. Afr. J. Sci.* **100**, 445–446.
3. White T.D. (2000). Jaws and teeth of *Australopithecus afarensis* from Maka, Middle Awash, Ethiopia. *Am. J. Phys. Anthropol.* **111**, 45–68.
4. Howell F.C. *et al.* (2004). *S. Afr. J. Sci.* **100**, 446.
5. White T.D. (2000). A view on the science: physical anthropology at the millennium. *Am. J. Phys. Anthropol.* **113**, 287–292.

#### Alain Beauvilain

Université de Paris X Nanterre, 200 avenue de la République, 92000 Nanterre Cedex, France.

#### Yves Le Guellec

Rue du Manoir, 76190 Yvetot, France.

#### Note from M. Brunet *et al.*

We thank Dr Beauvilain for indicating the errors in the legend to our figure, but would like to point out that the typographical error in the scale and the acci-

dental inversions of laterality information in our legend do not affect the anatomical data and interpretation we provided on the material presented. The correct legend should read as follows:

**Fig. 1.** Right hemi-mandible TM266-02-154-1 of *Sahelanthropus tchadensis*. A, B, and C: CT scans (courtesy: University Museum, University of Tokyo) at the level of the  $M_3$ . The mandibular corpus and the retained roots of the  $M_3$  are in light red. The crown of the third lower molar found separately and claimed to be a left one is in blue. A precise matching between the  $M_3$  crown and the corresponding roots in the hemi-mandible can be observed. The interstitial space between the  $M_3$  and its roots corresponds to thickness of the glue used to affix the tooth to its roots. **A**, Sagittal sections with mesial side at left — from left to right, CT scans are respectively shot at 3.33 mm, 4.41 mm, 7.83 mm, and 8.70 mm from the buccal edge of the tooth; **B**, transversal sections with lingual side at left — from left to right, CT scans are respectively shot at 2.67 mm, 3.69 mm, 4.11 mm, and 9.36 mm from the mesial edge of the tooth; **C**, sections parallel to the occlusal surface, at the cervix level and below, with mesial side at top — from left to right, CT scans are respectively shot at 6.93 mm, 7.14 mm, 7.44 mm, and 7.80 mm from the occlusal edge of the tooth. Mesially, the mesio-buccal and mesio-lingual roots remaining in the corpus (see F) appear in light red and show exact matching with the  $M_3$  crown (in blue); **D**, occlusal view of the complete specimen with its  $M_3$ ; **E**, occlusal view of the  $M_3$  roots; **F**, disto-lingual view of the join (white arrow) between the  $M_3$  and its distal root. All scale bars are 0.5 cm.